

# Possible nirmatrelvir/ritonavir-induced bradycardia in a patient with asymptomatic COVID-19

SAGE Open Medical Case Reports  
Volume 11: 1–5  
© The Author(s) 2023  
Article reuse guidelines:  
sagepub.com/journals-permissions  
DOI: 10.1177/2050313X231168304  
journals.sagepub.com/home/sco



Elizabeth DeMarco<sup>ID</sup>, Matthew Turnipseed, Brian Clarke and Farhan Qadeer

## Abstract

COVID-19 emerged in 2019 and was declared a pandemic by the World Health Organization in March 2020. COVID-19 is highly transmissible and can lead to bilateral pneumonia with severe respiratory failure. COVID-19 has led to more than 6.5 million deaths worldwide. The significant morbidity and mortality due to COVID-19 have resulted in the development of treatment modalities, such as novel antivirals, to reduce hospitalizations and progression of disease. In 2021, the US Food and Drug Administration authorized nirmatrelvir/ritonavir for emergency use in nonhospitalized patients with COVID-19. Nirmatrelvir is a newly developed protease inhibitor and is combined with a commonly used pharmacokinetic boosting agent, ritonavir. Given the novelty of nirmatrelvir/ritonavir, potential adverse effects remain uncertain. In this case, we describe a patient who was initiated on a course of nirmatrelvir/ritonavir and developed symptomatic bradycardia.

## Keywords

COVID-19, nirmatrelvir/ritonavir, bradycardia

Date received: 16 November 2022; accepted: 17 March 2023

## Introduction

COVID-19 is caused by severe acute respiratory syndrome coronavirus 2 (SARS-CoV-2). SARS-CoV-2 was first isolated in December 2019 in Wuhan, China and is highly transmissible through direct contact or respiratory droplets.<sup>1</sup> Lung epithelial cells are the primary target of the virus. Four structural proteins of SARS-CoV-2 are accountable for the pathogenicity of the virus—spike glycoprotein (S), small envelope glycoprotein (E), membrane glycoprotein (M), and nucleocapsid protein (N).<sup>2</sup> The SARS-CoV-2 virus binds to host receptors through its spike S-glycoproteins. Data suggest that the main receptor for SARS-CoV-2 entry into host cells is the angiotensin-converting enzyme 2 (ACE2) receptor, which is responsible for both respiratory and cardiac complications of COVID-19.<sup>3</sup> As of January 2023, COVID-19 has resulted in more than 6.5 million deaths worldwide, which has led to the rapid development of novel therapeutics such as antivirals to prevent COVID-19-related hospitalization, intubation, and death.

Patients infected with SARS-CoV-2 can have a range of clinical manifestations, from no symptoms to severe or critical illness. The National Institutes of Health (NIH) defines

severe illness as individuals who have SpO<sub>2</sub> less than 94% on room air, a ratio of arterial partial pressure of oxygen to fraction of inspired oxygen (PaO<sub>2</sub>/FiO<sub>2</sub>) less than 300 mmHg, a respiratory rate greater than 30 breaths per minutes (bpm), or lung infiltrations of greater than 50%. Critical COVID-19 illness includes patients who have respiratory failure, septic shock, and/or multiple organ dysfunction.<sup>4</sup> Patients with critical COVID-19 illness require a high level of clinical resources, and the influx of patients has put a strain on healthcare systems globally. Efforts have been made to identify patients at high risk and provide interventions to avoid disease progression. At this time, the percentage of patients who are asymptomatic at presentation and progress to clinical disease is not clearly defined. Characteristics of SARS-CoV-2, such as asymptomatic variants, long incubation period, and high level of transmissibility, make the

Shore Medical Center, Somers Point, NJ, USA

### Corresponding Author:

Elizabeth DeMarco, Shore Medical Center, 100 Medical Center Way, Somers Point, NJ 08244, USA.  
Email: edemarco9@gmail.com



elimination of the virus a challenge. COVID-19 has caused significant impact on the communities, economies, and health systems, which has led to the development of novel therapeutics such as nirmatrelvir/ritonavir (NMV/r).

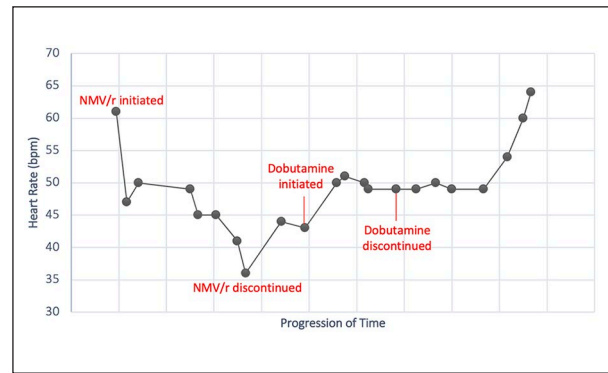
NMV/r was authorized by the US Food and Drug Administration (FDA) in December 2021 for the treatment of mild to moderate COVID-19 in adult and pediatric patients at least 12 years old with a positive COVID-19 test and who are at high risk of progressing to severe COVID-19, including hospitalization or death. The NIH recommends NMV/r as the preferred therapy for outpatients who are at high risk of progressing to severe COVID-19.<sup>4</sup> NMV/r was authorized under an Emergency Use Authorization (EUA), and there is a lack of data on adverse effects.

We present a case of a patient with asymptomatic COVID-19 and risk factors for developing severe COVID-19. She developed symptomatic bradycardia following the administration of three doses of NMV/r, which led to transfer to the intensive care unit (ICU) for administration of a dobutamine drip and close cardiac monitoring.

## Case

A 61-year-old Caucasian female with a medical history of peripheral arterial disease, hyperlipidemia, and previous tobacco use presented to the emergency department secondary to a 2-day history of midsternal chest pain. In 2019, she presented with acute occlusion of the right anterior artery and underwent a right common iliac artery stenting and stenting in the right tibial artery. The stent has since occluded in the right tibial artery. The patient was unvaccinated for COVID-19. She did not report any respiratory symptoms, nausea, or vomiting. The patient was admitted to the hospital to rule out acute coronary syndrome and was seen by the cardiology service. Initial laboratory tests, including troponins and D-dimer, were ordered, and results were not significant. Her vitals were all within normal limits, including her heart rate (HR) that remained in the 60s. A COVID-19 antigen and polymerase chain reaction (PCR) test were completed due to hospital policy for admission. The patient's both COVID-19 antigen and PCR were incidentally found to be positive. She was evaluated by the infectious disease service and was started on dexamethasone 6 mg intravenously (IV) daily and NMV/r after evaluating her risk factors for developing severe COVID-19 illness. NMV/r was initiated based on the data that suggest a significant reduction in death due to COVID-19 in high-risk patients.

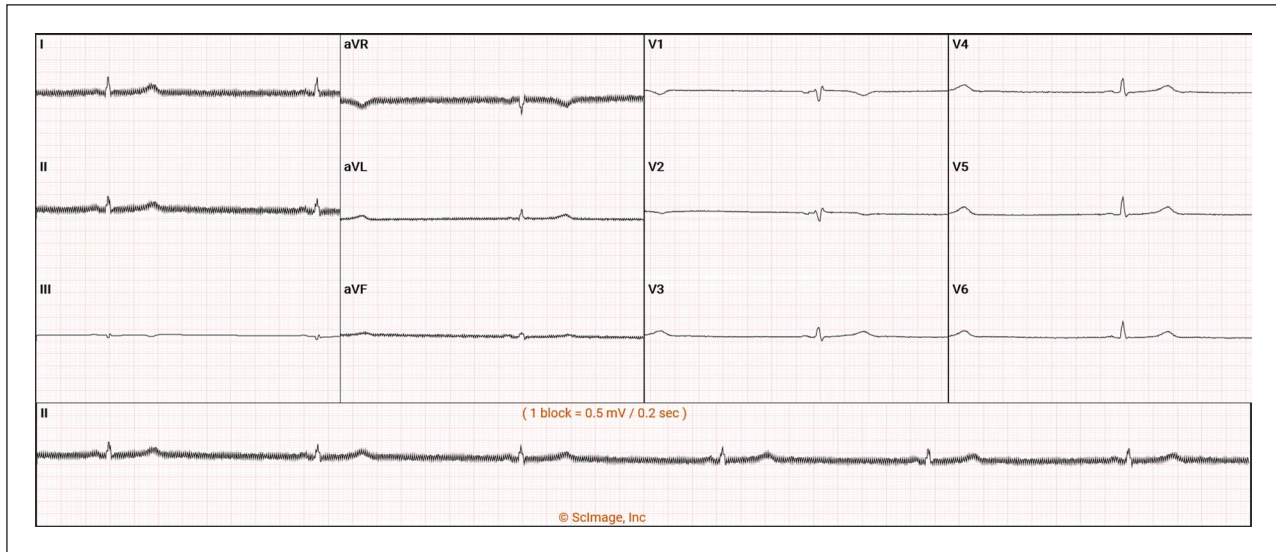Her medication list was reviewed by the team for drug interactions. Home medications included apixaban 5 mg oral daily, atorvastatin 40 mg oral at bedtime, and clopidogrel 75 mg oral daily and were all ordered at the time of hospital admission. According to the Liverpool COVID-19 Drug Interactions Database, co-administration of atorvastatin, a cytochrome P450 (CYP) 3A4 substrate, with NMR/r is not recommended unless clinically required for the acute



**Figure 1.** Graph demonstrating trend of the patient's HR in relation to time.

management of the patient. Holding atorvastatin for the short duration of anti-viral therapy minimizes the risk of adverse events due to drug interaction without negatively impacting the therapeutic effects.<sup>5</sup> The mean plasma half-life of the atorvastatin parent drug in humans is about 14 h, and the half-life of its equipotent metabolites is 20–30 h.<sup>6</sup> In patients aged  $\geq 65$  years at high risk of atherosclerotic cardiovascular disease, continuation of statin therapy can be considered to minimize the risk of atherosclerotic events during NMV/r therapy.<sup>7</sup> After reviewing this information, our patient's specific factors, and the limited number of statins on the hospital formulary, the team decided to hold atorvastatin during the duration of NMV/r therapy and resume 3 days following completion, as per the Liverpool COVID-19 Drug Interactions Database recommendations.<sup>5</sup> Apixaban is a substrate of p-glycoprotein and metabolized by CYP3A4. The package insert recommends either reduced dosing or avoided the use of apixaban with strong CYP3A4 and p-glycoprotein inhibitors.<sup>8</sup> Her apixaban dose was dose-adjusted from 5 mg twice daily to 2.5 mg twice daily, as recommended by the Liverpool COVID-19 Drug Interactions Database.<sup>5</sup> No other medication interactions were identified in her medication list. Her serum creatinine was under 1 mg/dL with an estimated glomerular filtration rate (eGFR) of  $\geq 60$  mL/min. She was ordered nirmatrelvir 300 mg and ritonavir 100 mg twice daily for a planned duration of 5 days.

Our patient's HR progressively declined after initiation of NMV/r, as illustrated in Figure 1. After receiving three doses of NMV/r, the patient was found to be in sinus bradycardia on cardiac telemetry with an HR in the mid 30s and her NMV/r was discontinued at this time. Her electrocardiogram (ECG) demonstrating sinus bradycardia is shown in Figure 2. She was not on any medications that would have contributed to her bradycardia, such as beta-blockers. The patient denied any chest pain, headache, dizziness, or blurry vision, and all electrolytes were within normal limits. She was administered atropine 0.5 mg IV twice, placed on transcutaneous pacer, and transferred to the medical ICU for close monitoring and further management. At this point, her blood



**Figure 2.** ECG demonstrating sinus bradycardia.

pressure dropped to 90 mmHg/45 mmHg, HR was 33 bpm, and her mean arterial pressure (MAP) was 60. Cardiology recommended to place the patient on a dobutamine drip at a starting rate of 2.5  $\mu\text{g}/\text{kg}/\text{min}$ . The dobutamine was titrated up to 5  $\mu\text{g}/\text{kg}/\text{min}$  to maintain an HR above 50 bpm, but the patient was unable to tolerate the medication due to episodes of palpitations. The drip was subsequently titrated back down and discontinued after a total duration of 10 h due to intolerance and improvements in her HR. Cardiology initiated an order for terbutaline tablet 5 mg by mouth to be administered if her HR dropped below 50 bpm. The patient was able to maintain her HR above 50 bpm and terbutaline was discontinued.

Our patient did not have any risk factors, such as hypoxemia or elevated inflammatory markers, that would predispose her for COVID-19-induced cardiac arrhythmias. She had a further workup that included cortisol and thyroid studies. Laboratory results revealed low cortisol levels but appropriate cosyntropin stimulation tests. The decision was made to perform a magnetic resonance imaging (MRI) of the brain to rule out a pituitary cause for her bradycardia. The MRI came back negative for any abnormalities. At discharge, the patient remained asymptomatic from COVID-19.

Based on the patient's clinical presentation of bradycardia after initiation of NMV/r and resolution of bradycardia after stopping NMV/r, it was thought that the patient had medication-induced bradycardia.

## Discussion

NMV/r is a novel antiviral medication that the FDA approved in December 2021 for emergency use in the treatment of mild to moderate COVID-19. In clinical trials, NMV/r was associated with an 88% reduction in hospitalization or death among high-risk, unvaccinated individuals with COVID-19.<sup>9</sup> It

contains the combination of nirmatrelvir and ritonavir. Nirmatrelvir is a novel second-generation protease inhibitor that is active against the Mpro protease. This protease is responsible for cleaving polyproteins in viral replication in all known human coronaviruses.<sup>10,11</sup> Ritonavir is a strong CYP3A4 inhibitor and is commonly utilized as a pharmacokinetic boosting agent for protease inhibitors. Co-administration of ritonavir with nirmatrelvir is required for the protease inhibitor to reach therapeutic levels in the plasma. Healthcare providers must be mindful of the possible drug interactions with ritonavir as a strong CYP3A4 inhibitor. As of November 2022, the NIH recommends using NMV/r orally twice daily for 5 days in nonhospitalized adults and pediatric patients aged  $\geq 12$  years and weighing  $\geq 40$  kg with mild to moderate COVID-19 who are at high risk of disease progression. Patients are classified as high risk if they have an underlying medical condition or risk factor that has published meta-analysis or systematic review demonstrating an increase in risk for at least one severe COVID-19 outcome.<sup>4</sup> Examples include asthma, cancer, coronary artery disease, chronic kidney disease, chronic lung diseases, diabetes mellitus, HIV, smoking, and use of immunosuppressive medications. In clinical trials, NMV/r was associated with an 88% reduction in hospitalization or death among high-risk, unvaccinated individuals with COVID-19. Renal impairment reduces excretion of nirmatrelvir. In patients with an eGFR of  $\geq 30$ –60 mL/min, a reduced dose is recommended. NMV/r is not recommended in patients with an eGFR less than 30 mL/min due to lack of data.<sup>6</sup> Our patient had normal renal function with an eGFR  $>60$  mL/min, and the standard dose of NMV/r was administered.

COVID-19 targets the ACE2 receptor, which is primarily expressed in the lung tissue and also present in the myocardium. Cardiac manifestations of COVID-19 include acute coronary syndrome, heart failure, myocarditis, arrhythmias,



and venous thromboembolism. Mechanisms behind cardiac complications of COVID-19 include direct damage of the myocardium and indirect damage through cytokine release syndrome, resulting in systemic inflammation.<sup>12</sup> Cardiac arrhythmias, including sinus bradycardia, can occur in ~6%–17% of patients with COVID-19.<sup>13</sup> Clinically stable patients, including patients who are asymptomatic, have a low incidence of arrhythmias, whereas patients admitted to the ICU have a much higher risk.<sup>14,15</sup> The mechanisms of which COVID-19 patients develop arrhythmias include acute myocardial injury, hypoxia, systemic inflammation, autonomic imbalances, electrolyte abnormalities, QT-prolonging medications, drug–drug interactions, and cardiovascular comorbidities.<sup>16</sup> Specifically, bradycardia may be caused by severe hypoxemia and injury of the sinus node by circulating cytokines. Bradycardia has been found to be a sign of the onset of a cytokine storm. Some reports describe a correlation between elevated troponin and C-reactive protein levels and incidences of ventricular arrhythmias.<sup>17</sup> Our patient was asymptomatic, with no hypoxia or other risk factors for developing a COVID-19-related cardiac arrhythmia. The team ruled out her arrhythmia to be COVID-19-induced.

The EPIC-HR was a large randomized controlled study that compared NMV/r to placebo in patients aged  $\geq 18$  years with mild to moderate COVID-19 who were at high risk of clinical progression and were within 5 days of symptom onset. High risk of clinical progression was defined as unvaccinated against COVID-19 and the presence of at least one risk factor for progression to severe disease.<sup>18</sup> The trial demonstrated that NMV/r reduced the risk of hospitalization or death through Day 28 by 89% compared to placebo.<sup>10,18</sup> Patients were included in the EPIC-HR safety analysis if they received at least one dose of NMV/r or placebo. The most common adverse effects of NMV/r were dysgeusia, diarrhea, hypertension, and myalgia.<sup>17</sup> The FDA fact sheet for providers lists a potential risk of bradycardia only when the patient is concomitantly taking ivabradine or eplerenone, which our patient was not on. This risk is due to ritonavir's inhibition of CYP3A4 enzyme.

A small amount of data is available to support ritonavir contributing to heart arrhythmias. Lopinavir/ritonavir is an HIV-1 antiviral trialed in COVID-19 patients early in the pandemic. A large, randomized controlled trial in May 2020 evaluated lopinavir-ritonavir in adults hospitalized with COVID-19 and noted a very small incidence of rhythm disorders.<sup>19</sup> In 2020, a review of a French health system reported 22 cases of arrhythmias in elderly patients taking lopinavir/ritonavir, including 5 cases of sinus bradycardia.<sup>20</sup> A retrospective study published in 2020 evaluated the incidence of bradycardia in COVID-19 patients receiving lopinavir/ritonavir in the ICU. The study included 41 critically ill COVID-19 patients who received lopinavir/ritonavir. There were nine cases of bradycardia occurring in patients at least 48 h after initiation, and the bradycardia resolved after discontinuation or dose-reduction of lopinavir/ritonavir.<sup>21</sup> Confounding variables such as

the cardiovascular effects of COVID-19 disease, severity of COVID-19 disease, cardiac comorbidities, and drug interactions should be considered.

Among other viral protease inhibitors, ritonavir has shown in vitro dose-dependent activity blocking human ether-a-go-go-related gene (HERG) potassium channels involved in cardiac repolarization. This activity can elongate the QT interval.<sup>22</sup> These data suggest there is potential for viral protease inhibitors, such as the components of NMV/r, to cause bradycardia. Post-marketing surveillance is essential to identify clinically significant adverse events.

## Conclusion

COVID-19 continues to impact our communities, and it is expected that new antivirals such as NMV/r will continue to be prescribed to patients. This case report demonstrates a possible side effect of NMV/r, which is noteworthy given the lack of data on the side effect profile of the medication. As NMV/r continues to be prescribed in the outpatient setting, healthcare providers should monitor patients and counsel about possible side effects, such as symptomatic bradycardia. Further randomized controlled trials are warranted to assess the possible causality and incidence of bradycardia in patients who are prescribed NMV/r.

## Acknowledgements

We would like to thank the patient who entrusted us to be part of her case and permitted us to share her case.

## Authors' contributions

**Elizabeth DeMarco:** Made a substantial contribution to the concept or design of the work, or acquisition, analysis, or interpretation of data; Drafted the article or revised it critically for important intellectual content; Approved the version to be published; Each author should have participated sufficiently in the work to take public responsibility for appropriate portions of the content.

**Matthew Turnipseed:** Made a substantial contribution to the concept or design of the work, or acquisition, analysis, or interpretation of data; Drafted the article or revised it critically for important intellectual content; Approved the version to be published; Each author should have participated sufficiently in the work to take public responsibility for appropriate portions of the content.

**Brian Clarke:** Made a substantial contribution to the concept or design of the work, or acquisition, analysis, or interpretation of data; Drafted the article or revised it critically for important intellectual content; Approved the version to be published; Each author should have participated sufficiently in the work to take public responsibility for appropriate portions of the content.

**Farhan Qadeer:** Made a substantial contribution to the concept or design of the work, or acquisition, analysis, or interpretation of data; Drafted the article or revised it critically for important intellectual content; Approved the version to be published; Each author should have participated sufficiently in the work to take public responsibility for appropriate portions of the content.

## Declaration of conflicting interests

The author(s) declared no potential conflicts of interest with respect to the research, authorship, and/or publication of this article.

## Funding

The author(s) received no financial support for the research, authorship, and/or publication of this article.

## Ethical approval

Our institution does not require ethical approval for reporting individual cases or case series.

## Informed consent

Written informed consent was obtained from the patient(s) for their anonymized information to be published in this article.

## ORCID iD

Elizabeth DeMarco  <https://orcid.org/0000-0002-8038-3640>

## References

- Gattinoni L, Gattarello S, Steinberg I, et al. COVID-19 pneumonia: pathophysiology and management. *Eur Respir Rev* 2021; 30(162): 210138.
- Gusev E, Sarapultsev A, Solomatina L, et al. SARS-CoV-2-specific immune response and the pathogenesis of COVID-19. *Int J Mol Sci* 2022; 23(3): 1716.
- Wan Y, Shang J, Graham R, et al. Receptor recognition by the novel coronavirus from Wuhan: an analysis based on decade-long structural studies of SARS coronavirus. *J Virol* 2020; 94(7): e00127.
- National Institutes of Health. COVID-19 treatment guidelines panel: coronavirus disease 2019 (COVID-19) treatment guidelines, <https://www.covid19treatmentguidelines.nih.gov/>
- University of Liverpool COVID-19 Drug interaction database, <https://www.covid19-druginteractions.org/> (accessed 26 January 2023).
- Atorvastatin* (Package insert). Dublin, Ireland: Pfizer Inc, 2019.
- Vuorio A, Raal F and Kovanen PT. Drug-drug interaction with oral antivirals for the early treatment of COVID-19. *Int J Infect Dis* 2023; 127: 171–172.
- Apixaban* (Package insert). New York: Bristol-Myers Squibb, 2021.
- Food Drug Administration. Fact sheet for healthcare providers: emergency use authorization for Paxlovid, 2022, <https://www.fda.gov/media/155050/download>
- Pillaiyar T, Manickam M, Namasivayam V, et al. An overview of severe acute respiratory syndrome-coronavirus (SARS-CoV) 3CL protease inhibitors: peptidomimetics and small molecule chemotherapy. *J Med Chem* 2016; 59(14): 6595–6628.
- Owen DR, Allerton CMN, Anderson AS, et al. An oral SARS-CoV-2 M(pro) inhibitor clinical candidate for the treatment of COVID-19. *Science* 2021; 374(6575): 1586–1593.
- Chang WT, Toh HS, Liao CT, et al. Cardiac involvement of COVID-19: a comprehensive review. *Am J Med Sci* 2021; 361(1): 14–22.
- Wang D, Hu B, Hu C, et al. Clinical characteristics of 138 hospitalized patients with 2019 novel coronavirus-infected pneumonia in Wuhan, China. *JAMA* 2020; 323: 1061–1069.
- Sala S, Peretto G, De Luca G, et al. Low prevalence of arrhythmias in clinically stable COVID-19 patients. *Pacing Clin Electrophysiol* 2020; 43(8): 891–893.
- Lazaridis C, Vlachogiannis NI, Bakogiannis C, et al. Involvement of cardiovascular system as the critical point in coronavirus disease 2019 (COVID-19) prognosis and recovery. *Hellenic J Cardiol* 2020; 61(6): 381–395.
- Manolis AS, Manolis AA, Manolis TA, et al. COVID-19 infection and cardiac arrhythmias. *Trends Cardiovasc Med* 2020; 30(8): 451–460.
- Azevedo RB, Botelho BG, Hollanda JVG, et al. Covid-19 and the cardiovascular system: a comprehensive review. *J Hum Hypertens* 2021; 35(1): 4–11.
- Hammond J, Leister- Tebbe H, Gardner A, et al. Oral nirmatrelvir for high-risk, nonhospitalized adults with COVID-19. *N Engl J Med* 2022; 386(15): 1397–1408.
- Cao B, Wang Y, Wen D, et al. A trial of lopinavir-ritonavir in adults hospitalized with severe Covid-19. *N Engl J Med* 2020; 382(19): 1787–1799.
- Fresse A, Viard D, Romani S, et al. Spontaneous reported cardiotoxicity induced by lopinavir/ritonavir in Covid-19. An alleged past-resolved problem. *Int J Cardiol* 2021; 324: 255–260.
- Beys C, Martin N, Hermida A, et al. Lopinavir-ritonavir treatment for COVID-19 infection in intensive care unit: risk of bradycardia. *Circ Arrhythm Electrophysiol* 2020; 13(8): e008798.
- Lamothe SM, Guo J, Li W, et al. The human ether-a-go-go-related gene (hERG) potassium channel represents an unusual target for protease-mediated damage. *J Biol Chem* 2016; 291(39): 20387–20401.